

CASE STUDY

- 98% WOUND REDUCTION IN 17 WEEKS
- 16 ACTIGRAFT APPLICATIONS

PATIENT:

87 Year Old, Male

PAST MEDICAL HISTORY:

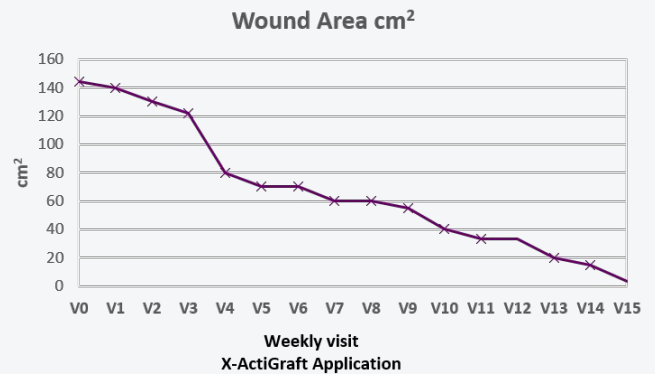
Venous Insufficiency, Controlled diabetes 2, Hypertension

WOUND HISTORY:

- VLU on calf and shin, heavy exudating

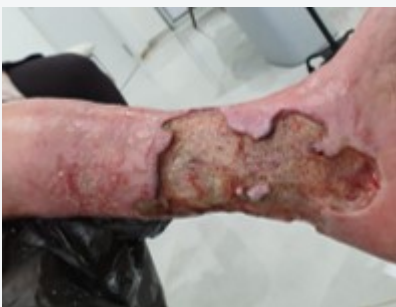PAST TREATMENTS:

Ozone gas treatment for 4 years- deterioration
Advanced wound dressings for past 2 years



ACTIGRAFT TREATMENT PROGRESSION:

Week 1



Week 17

